

Study the Adverse Effect of E, Cigarette and Conventional Cigarette in Kidneys, Stomach and Testes in Rats in Comparison with Control Group

Raghad Jawad Salman

Department of Anatomy and Medical Biology, College of Medicine Wasit, University

Hakim Bahlok Jebur

Department of Pharmacology, College of Medicine, Wasit University, Iraq

Hasan Ikareim Idbeis

Department of Microbiology, College of Medicine, Wasit University, Iraq

Article Information

Received: February 12, 2023

Accepted: March 13, 2023

Published: April 14, 2023

ABSTRACT

Background: The traditional cigarette is known for its harmful effects on most organs of the body, with pathological effects. Several methods have been suggested to quit smoking or reduce its harmful effects. One of these proposed solutions is the use of electronic cigarettes while promoting them as an alternative to traditional cigarettes without side effects. Recent studies have proven that there are effects of these cigarettes that may differ or are similar to the effects of traditional cigarettes, but less severe.

Objectives: This study aims to evaluate the effects of the consumption of e-cigarettes and conventional cigarettes in comparison to the control group on kidney, stomach, and testes tissue and investigate the role played by e-cigarettes to stop conventional smoking according to survey study.

Study Design: An experimental study which lasted for 30 days was conducted at the Animal House of the College of Sciences, Wasit University, Iraq. Survey parts were done by distributing questionnaires in printed and electronic forms.

Method: For 30 days, nicotine-containing vapour (3.6 mg/mL) and traditional cigarettes were delivered to 25 male Wistar rats. The creatures were split into three groups: Group A (5 rats) served as the control group without receiving any nicotine exposure, Group B (10 rats) received traditional smoke, and Group C (10 rats) received liquid vapour from an electronic cigarette.

Result: Numerous differences between the experimental groups B and C and the control group were found. The renal effect of conventional cigarettes was represented by focal necrosis in the Henle tubule resulting in atrophy in glomeruli less effect was noticed in the e-cigarette group. Stomach tissue in the conventional cigarette group show focal necrosis in glandular and non-glandular tissue, congestion of blood vessels and haemorrhage in the submucosa of the stomach while in the e-cigarette group there was finger-like a project in of epithelium of non-glandular tissue, and high keratinization in the epithelium of stomach was seen in both groups. Testes tissue in conventional cigarettes shows atrophy and degeneration in the seminiferous tubule and vacuole in the seminiferous tubule of the testes. While in the e-cigarette group there were significant signs its hyperplasia in the smooth muscle of the tail of the epididymis.

Conclusion: It was found that electronic cigarette has side effects on the health of vital organs and tissues of the body, but compared to a regular cigarette the effect is less. The electronic cigarette can be adopted as an alternative to the regular cigarette or as a way to quit smoking, but this depends on the smoker's conviction of it as an alternative, as well as choosing a cigarette with low nicotine levels.

Introduction

Smoking damages almost all of the body's organs and causes sickness and impairment. Over 16 million Americans are affected by a condition brought on by smoking. At least 30 people live with a major smoking-related disease for every smoker who passes away (Choi et al., 2017). In addition to emphysema and chronic bronchitis, smoking also increases the risk of developing cancer, heart disease, stroke, lung conditions, diabetes, and chronic obstructive pulmonary disease (COPD). Smoking also raises the chance of developing TB, several eye conditions, and immune system issues, such as rheumatoid arthritis (Sabashvili et al., 2018).

Smokers' higher blood levels of cadmium and lead, which cause glomerular dysfunction, also have an impact on the kidney. Nicotine speeds up nephropathies, which is followed by renal failure brought on by type 1 diabetes. At least in part, the stimulation of the sympathetic nervous system that results in an increase in blood pressure is what causes cigarette smoke to cause kidney injury (Cooper RG, 2006). The stomach is the second organ that smoking might harm since it increases the chance of gastrointestinal illnesses such as peptic ulcer, Crohn's disease (CD), and various malignancies. Mucosal injury, alterations in gut irrigation, and a weakened mucosal immune response are among the theories put up to explain how smoking contributes to these illnesses (Berkowitz L. et al., 2018). Because of how smoking affects the sex organ, notably the testis, fertility may decline. Reduced sperm content and motility in the epididymis may be the cause of this impact. Smoking impairs sperm maturation and spermatogenesis as well as the secretory activity of the Leydig cells. Additionally, smoking has a negative impact on the ability of sperm to fertilize both in vivo and in vitro (Yamamoto Y. et al., 1998).

Because of these negative consequences, research indicates that around 75 percent of smokers desire to stop. However, because smoking is so addicting, quitting is challenging and repeated relapses are prevalent among those who attempt. The effectiveness of different smoking cessation therapies is still being studied. The chance of quitting has been demonstrated to increase with the use of NRT, bupropion, varenicline, and cytisine, with varenicline providing the highest effect. However, customer attractiveness and product satisfaction for these goods are very low (Grana RA and Ling PM. 2014; Kosmider L. et al., 2014).

The capacity of electronic cigarettes (e-cigarettes) to accurately mimic the visual and behavioral experience of smoking while also providing a dosage of nicotine without involving the burning of tobacco has attracted the attention of smokers in recent years. Therefore, e-cigarettes may have potential functions in tobacco damage reduction and quitting smoking (Trtchounian A. et al., 2010; Vansickel AR and Eissenberg T. 2013).

Electronic cigarettes (e-cigarettes) were developed in their current form by Chinese pharmacist Hon Lik in the early 2000s. They are products that deliver a nicotine-containing aerosol (commonly known as vapour) to users by heating a solution typically made of propylene glycol or glycerol (glycerin), nicotine, and flavoring agents (Grana R. et al., 2013).

Aerosol from e-cigarettes is not secure. The addictive substance found in traditional cigarettes, cigars, and other tobacco products, nicotine, is present in the majority of e-cigarettes. Users of e-cigarettes may possibly expose themselves and others to dangerous chemicals, such as heavy metals, volatile organic compounds, and ultrafine particles that can be absorbed deeply into the lungs, in addition to nicotine (Office of the Surgeon General 2016). A recent investigation on the

impact of e-cigarette vapour on lung function found that using them for 5 minutes increased total respiratory impedance, respiratory flow resistance, and overall peripheral airway resistance in 30 healthy smokers. These findings emphasize the potential short- and long-term consequences of vapours comparable to those from e-cigarettes, even if they cannot be immediately generalized to e-cigarette usage (Vardavas CI. et al., 2012).

A research that shows probable nephrotoxicity of e-cigarette fluid in mice also implies kidney injury (Golli NE. et al., 2016). Additionally, a new study demonstrates how e-cigarette use harms the stomach by causing increased inflammation owing to damaged intestinal barriers (Sharma A. et al., 2021). Another damaged organ is the testes, where a research on rats exposed to e-cigarettes reveals a decreased relative testis weight and increased levels of lactate dehydrogenase (LDH), a hallmark of tissue destruction, as well as a deficiency in important enzymes in the steroidogenesis pathway (Vivarelli F. et al., 2019).

Materials and methods

From July 10 to September 10 of 2021, this study was carried out in the School of Medicine at Wasit University. Animals were weighed weekly throughout the experiment, starting at a weight of about 170 grams. They were then sorted into three groups based on how well they adapted to their new environment: Group A (5 rats) served as the control group without receiving any nicotine exposure, Group B (10 rats) received traditional smoke, Group C (10 rats) received liquid vapour from an electronic cigarette. E-cigarettes and traditional cigarettes were used to expose male Wistar rats to varied nicotine concentrations (3 and 6 mg/mL) of vapour for 45 days (0.3 mg Nicotine) (Troiano et al., 2019).

The Biomedical ethics committee at the college of medicine/Wasit University approved the protocol for this study.

Rats were used as a model for humans exposed to e-cigarette vapour and traditional cigarette smoke, in the current study. In terms of animal exposure to e-cigarette vapour, the current study used a similar methodology to that suggested by Canistro et al., 2017.

Our exposure regimen was based on techniques that had previously been used and were discussed by Manchio et al. (2009) and Karayel et al (2015). For 45 days straight, rats in the experimental groups were kept in a smoking room for one hour each day.

The conventional cigarette smoke group was given cigarettes (KENT 0.3 mg Nicotine; International). Electronic cigarettes (Vooopoo Drag Max 177W Pod Mod KIT) were chosen for the experiment because they are the most popular brand and employ fluid with nicotine concentrations of 3 and 6 mg/mL.

Tissue collection

The tissue was collected after 30 days when exposed of rats to conventional cig. and e-cig. In preparing rats for histopathological study, animals were anaesthetized by inhalation of chloroform and then sacrificed by decapitation according to the Ministerial procedures approved for the species. Then kidney, stomach, and testes tissue were collected and kept in a container have 10% of formalin. After that histological preparation of tissue and staining by Hematoxylin and eosin stain was done and a light microscope was used to examine the slides of lung tissue.

Apparatus

The smoking room in the current study was converted from an anaerobic box chamber (Figure 1). The box utilized in this project was created for the local market using the specifications for the chamber that Montanari et al., (2020), which were as follows: sealed exposure chambers were modified standard rat cages (259mmX234mmX209mm) to deliver vaporized nicotine and conventional cigarette smoke into the chambers (Figure 1). To supply nicotine puffs from both

electronic and traditional cigarettes to each chamber, MedPC IV software activated three e-Vape generator controllers set at 4.5 watts. To maintain an airflow rate of around 3.5 L/min, the air chamber was vacuum-controlled. Nicotine was blended with the surrounding air stream and fed to the chambers through polyethylene tubing attached to the cartridges after the generator controls were activated. Vacuum air pumps attached to the chambers sucked smoke and nicotine vapour out of the chamber and into the exhaust (Figure) (Montanari and Christian, 2020).

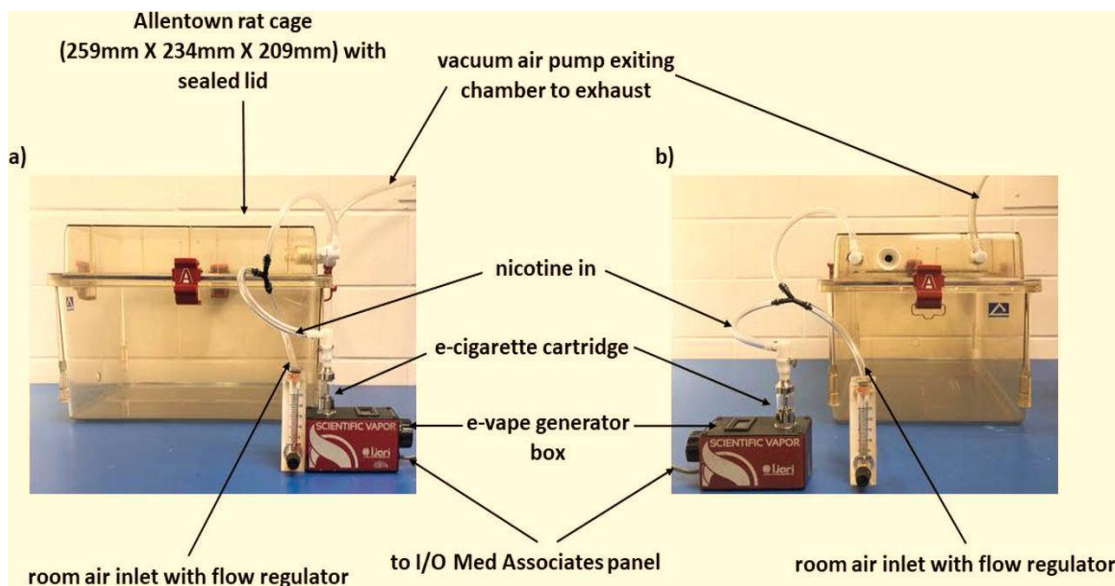


Figure 1: Front (panel a) and side (panel b) views of the model of the apparatus were modified in the present study (Montanari et al., 2020).

Questionnaire

A questionnaire was distributed in Wasit, Iraq from the 20th of May to the 5th of September 2022. Approval of the study protocol and written consent were obtained before data collection. Then we started writing the questionnaire. The preliminary version of the questionnaire (a modified Arabic version) was finalized for application. The 16-item structured questionnaire included items such as age, gender, family income, educational levels of the person, current and previous use of any tobacco product, the person's smoking duration, reasons and source of the idea of using an e-cigarette, knowledge about the harmful effects of ecigarette, and idea of quit smoking, and others. People were given the opportunity to participate or not, and the questionnaire was presented outside of the classroom after a brief explanation of the study's goals and a basic introduction. Participants were educated on the significance of providing an honest response, and assistance was offered to respondents who needed clarification on any of the questions. The replies were anonymous, and participants were ensured of the confidentiality of their comments (Informed verbal permission). Each participant had their answers to the questionnaire kept private in order to encourage the open exchange of information. The questionnaire was distributed in two ways: first, in printed form, and it was distributed to several electronic cigarette shops. Then the owner distributes the questionnaire to the customers. Secondly, the electronic form which distributed to several e-cigarette smokers, and they were filled out electronically. The total number of samples is 222 and includes 197 males and 25 females, with ages ranging from 15-50. After collecting the questionnaire samples, data were entered into an Excel spreadsheet and analysis was performed by using SPSS version 25. 10-

Result and discussion

Microscopic change of the kidney

The light microscopic examination of hematoxylin and eosin staining of the kidney section of control rats (group A) revealed the normal basic structure of the kidney which includes glomeruli,

renal tubules and loops of Henle (Figure 2-A). compare to the tissue of the kidney in group B (conventional cigarettes) of rats showed focal necrosis in the Henle tubule and lymphocyte infiltration (Figure 2-B) which resulted in atrophy in glomeruli and increase distance with bowman's capsule (Figure 2-C). And there was congestion of renal blood vessels, infiltration of lymphocyte interstitial tissue and intraluminal casts observed in the tubules near to renal medulla (Figure 2-D). But group C (E. cigarette) of rats showed focal necrosis of convoluted tubule and renal congestion (Figure 2-E) and also found intraluminal casts in the tubules near to renal medulla (Figure 2-F). The current study noticed the effect of conventional cigarettes is more diverse than e-cigarettes on the kidney tissue of rats but this cannot prevent it can lead to this result in the long term.

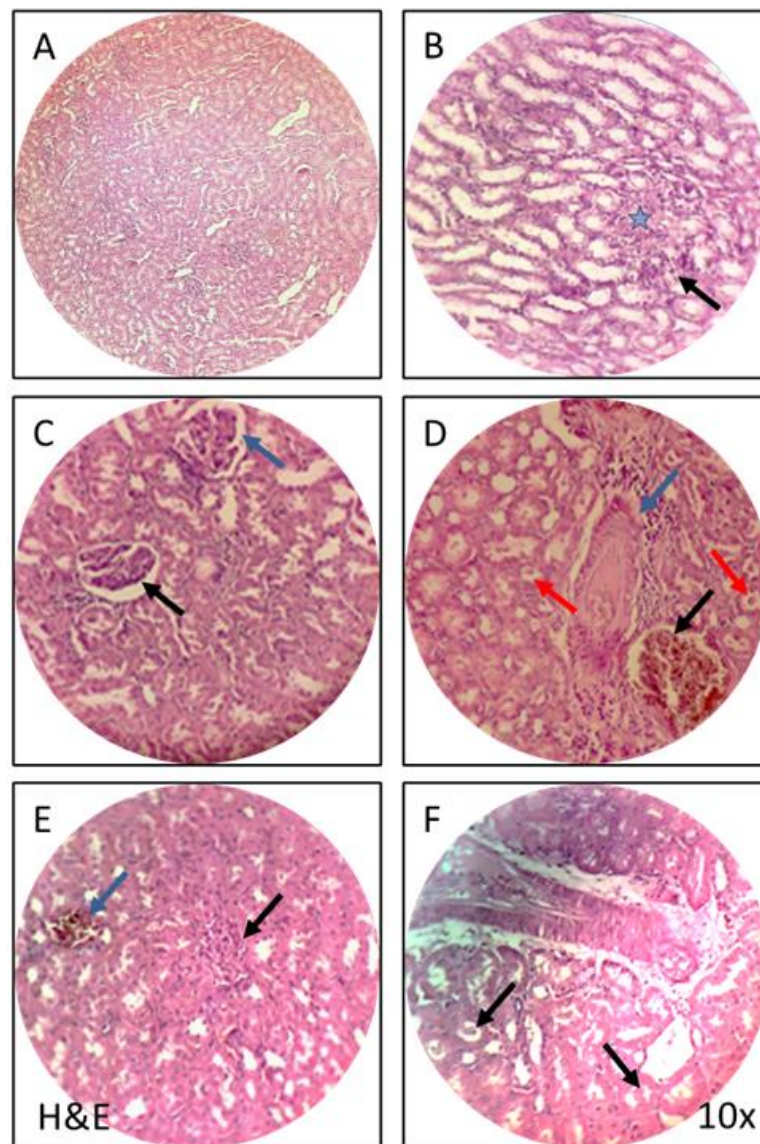


Figure 2: Kidney tissue of control, conventional cigarette, and e-cigarette. H&E, 10X. **A.** Normal histological tissue of the kidney in control rats. **B.** Histological tissue of the kidney in rats in which exposed to the conventional cigarettes show focal necrosis in henle tubule (blue stare) and lymphocyte infiltration (black arrow). **C.** Tissue of the kidney in rats in which exposed to the conventional cigarettes, there was atrophy in glomeruli (black arrow) and increase distance with bowman's capsule (blue arrow). **D.** Tissue of the kidney in rats in which exposed to the conventional cigarettes there was congestion of renal blood vessel (black arrow), infiltration of lymphocyte interstitial tissue (blue arrow) and intraluminal casts in the tubules red arrow. **E.** Tissue of the kidney in rats in which exposed to e-cigarette there was focal necrosis of convoluted tubule (black arrow) and renal congestion (blue arrow). **F.** Tissue of the kidney in rats in which exposed to E. cigarette show intraluminal casts in the tubules (black arrow).

Discussion of kidney result

The present study noted that rats in which exposed to conventional cigarettes have focal necrosis in the Henle tubule and lymphocyte infiltration due to the nicotine effect and other toxic substances in which found in conventional cigarettes which cause damage to kidney tissue and nephrotoxic effect. Midhat Syed et al. (2020) found collapsed necrotic in some of the renal corpuscles of the glomerulus. According to Arany et al. (2011), nicotine, one of tobacco's main chemical constituents, may have a significant role in the etiology of renal disorders and aggravate acute renal ischemia damage. The current study noted atrophy in glomeruli, increase distance from bowman's capsule and lymphocyte infiltration interstitial tissue because the toxic material in conventional cigar causes chronic inflammation in the kidney and this result is supported by Midhat Syed et al.(2020). Adekomi D. A. et.al. (2011) showed that exposure to smoke extracts of tobacco nicotine result in renal cortex interstitial glomerular haemorrhage and there was also shrinkage of the glomerulus. That may explain the congestion of renal tubules and blood vessels in the current study, in the opposite other authors (Toklu H. et al., 2010, Adedayo AD. et al., 2011, Ismail HAA., 2016, Al- Awaida, 2014), were indicated modest interstitial congestion, localized hemorrhage, and a persistent interstitial inflammatory infiltrate; these findings are consistent with those of earlier indexing investigations (Halimi JM, et, al.,1998) Smokers' elevated systemic blood pressure, loss of the Renoprotective mechanism, and further decline in glomerular filtration rates and renal artery stenosis incidence are all linked to an increased mortality risk in individuals with end-stage renal disease. While in rats group in which exposed to e-cigarettes showed focal necrosis of convoluted tubule and renal artery congestion, and the current study agrees with the opinion of Gagandeep Kaur et al., (2018), which is that although electronic cigar nicotine less than conventional cigarettes but remains harmful whether little or a lot. Orth et al., (1997) suggest that tobacco smoking accelerates the progression of chronic kidney disease. Also, the current study found in both groups (conventional and e-cigarette) rats intraluminal casts in the tubules near to renal medulla. While Metwally et al. (2015) report that rats exposed to nicotine showed some tubules appeared solid cord pink eosinophilic hyaline material, Midhat Syed reported dilation of urinary space, shrunken and distorted glomeruli, with some renal tubules displaying the solid cord-like pattern and some showing eosinophilic material in the lumen, focal inflammatory infiltrates, and renal congestion. According to Narges El. Golli et al. (2016), e-liquid may affect antioxidant defense and cause a small alteration in renal function parameters.

Microscopic change of stomach

In the current study exposed rats to conventional cigarettes reveals an alteration in the tissue of the stomach compared to control rats that have intact layers of the stomach (Figure 3-A), but we found in the stomach tissue of rats that were exposed to conventional cigarette there was focal necrosis in glandular and non-glandular tissue of the stomach (Figure 3-B). Also, there was high keratinization of non-glandular tissue in the stomach epithelium (Figure 3-C), congestion of blood vessels and haemorrhage in the submucosa of the stomach (Figure 3-D). While in groups of rats in which exposed to electronic cigarettes there was a finger-like project in of epithelium of non-glandular tissue of the stomach (Figure 3-E), also noted high keratinization in the epithelium of the stomach (Figure 3-F).

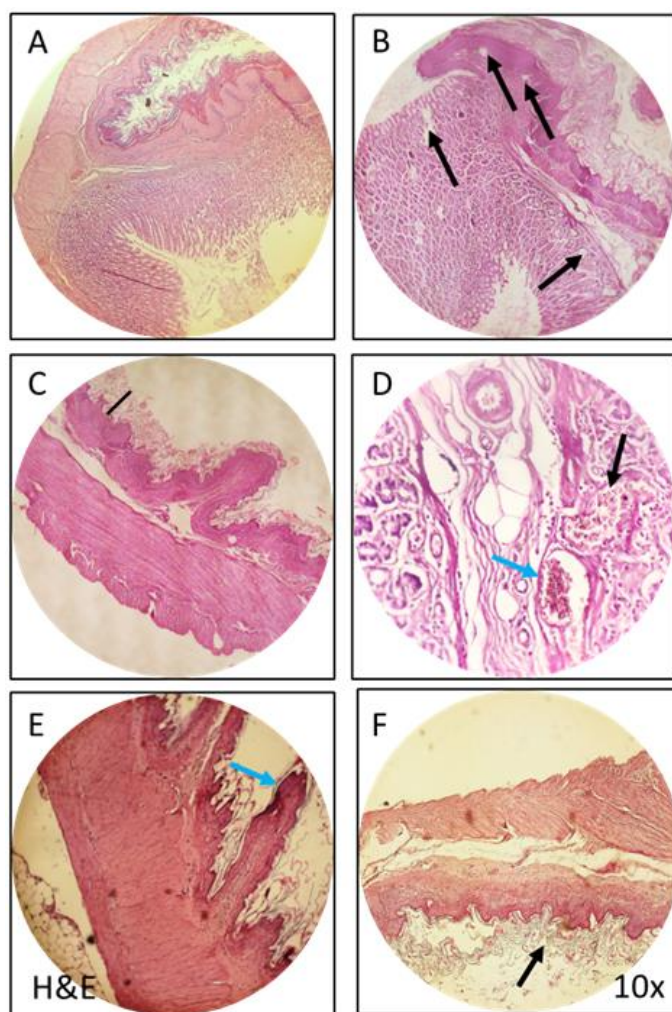


Figure 3. Stomach tissue of control, conventional cigarette, and e-cigarette. H&E, 10X. **A.** The normal tissue of stomach of control rats. **B.** The tissue of stomach of rats in which exposed to conventional cigarette, there is focal necrosis in glandular and nonglandular tissue of the stomach (black arrow). **C.** The tissue of stomach of rats in which exposed to conventional cigarette there is high keratinization of non-glandular tissue (black line). **D.** The tissue of stomach of rats in which exposed to conventional cigarette there is congestion of blood vessel (blue arrow) and hemorrhage in sub mucosa of stomach (black arrow). **E.** The tissue of stomach of rats in which exposed rats in which exposed to electronic cigar there is finger like project on the epithelium of non glandular tissue of stomach (blue arrow). **F.** The tissue of stomach of rats in which exposed to electronic cigar there is high keratinization in epithelium (black arrow).

Discussion of stomach results

In the tissue of the stomach of rats in which exposed to conventional cigarette noted there was focal necrosis in glandular and non-glandular tissue of the stomach, congestion of blood vessels and haemorrhage in the submucosa of the stomach this occurred due to the toxic material in traditional cigarette-like nicotine in which effect on the functional secretion of stomach and increase secretion of acidic substance and this substance has a very harmful effect on the stomach lining and lead to necrosis in the stomach lining. In agreement with Gomez and colleagues (1996), it was discovered that nicotine treatment in rats decreased gastrin serum levels and decreased gastrin expression by G cells due to increased stomach acid output. Similar findings were made by other researchers (Soad Shaker Ali et al. 2015), who discovered that nicotine administration has a negative effect on the gastric structure and is linked to increased levels of gastrin and decreased levels of PGE2. They also discovered that nicotine-induced gastric mucosa blood vessel congestion, ulceration, and small hemorrhages are among the side effects of nicotine use on the stomach. Other researchers Hui *et al.* (1991), showed that oral nicotine administration

causes microscopic injury of the gastric mucosa. The delivery of nicotine at a "smoking dosage" enhanced acid secretion, according to research by Irfan, Affan B., and Conklin, Daniel J., et al. (2019). This effect is likely due to a vagal route. Additionally, according to Chow et al. (1998), smoking causes ulcers to develop and slows down their healing by increasing the release of pepsin and acid, creating more free radicals, and allowing neutrophils to infiltrate the area. Free radicals, eicosanoids, thromboxanes, and leukotrienes have all been linked to the pathophysiology of different types of gastric mucosal damage. Whittle BJR. (1989) discovered variations in gastric mucosal blood flow caused by the local production of vasoactive or cytotoxic mediators. Furthermore, both the traditional and e-cigarette-using groups of rats in the current study had significant levels of keratinization. Other research (Maity et al. 2003) showed that nicotine and cigarette smoke decreased the levels of prostaglandins and epidermal growth factor, which are crucial for healing stomach ulcers. Me et al. (2000) observed a decrease in mucus, prostaglandin (PG), and epidermal growth factor production as well as stomach blood flow.

Microscopic change of tsetse

In experimental animals exposed rats to conventional cigarettes and e-cigarettes after one month twice a day to vapour containing nicotine lead to histopathological changes in testes including atrophy and degeneration in seminiferous tubules in groups of rats in which exposed to conventional cigarettes (Figure 4-A), compared to the tissue of testes in control rat have normal seminiferous tubule and epididymis in testicular tissue (Figure 4-B), also noted vacuole in the seminiferous tubule of the testes (Figure 4-C). While in groups of rats in which exposed to electronic cigarettes there were significant signs its hyperplasia in the smooth muscle of the tail of the epididymis (Figure 4-D). The current study showed that the most affected organ in the e-cigarette group is the epididymis while conventional cigarettes mostly affect the seminiferous tubule.

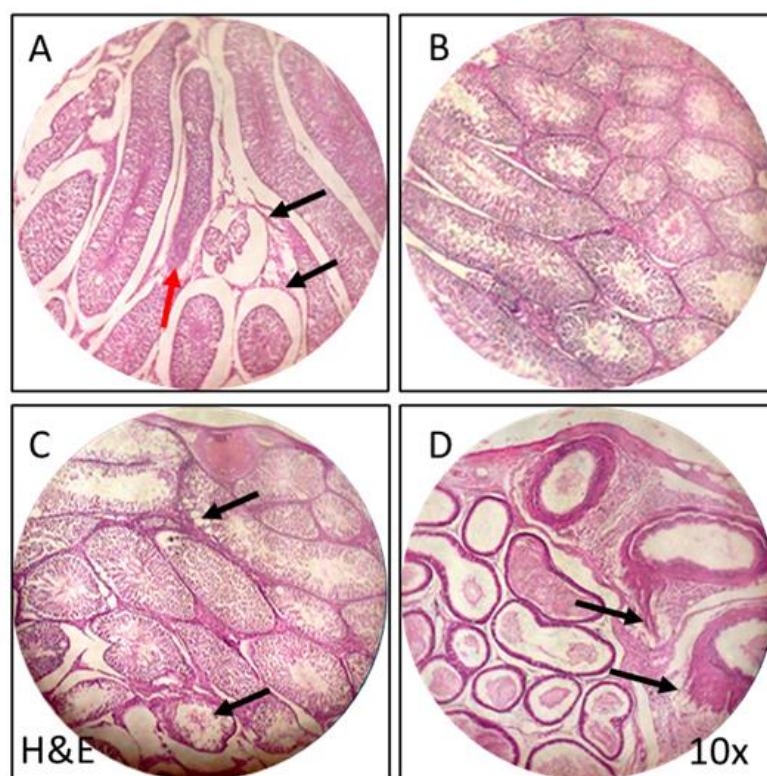


Figure 4. Testis and epididymis tissue of control, conventional cigarette, and e-cigarette. H&E, 40X. **A.** Tissue of testes of rats after exposed to conventional smoking, there is atrophy (black arrow) and degeneration in seminiferous tubule (red arrow). **B.** Tissue of testes of control rats. **C.** Testicular tissue of rats after exposed to conventional smoking, there is vacuole in seminiferous tubules (black arrow). **D.** Tissue of testes of rats after exposed to electronic cigarette there was hyperplasia in tail of epididymis (black arrow).

Discussion of the testes

The current study illustrates a histopathological change in testicular tissue of the rats exposed to conventional cigarettes including atrophy, vacuole and degeneration mostly affect seminiferous tubules compared to the epididymis of the testes which agreed with Kamila S. et.al., (2020) were They observed that some of the seminiferous tubules were severely damaged, exhibiting collapse or degeneration of spermatogenic cells with a subsequent arrest of the spermatogenic process. This is consistent with the findings of a previous study (Kovac, J.R. et al., 2015), which found that smoking men had lower levels of semen parameters and a higher proportion of sperm with abnormal morphology. It has also been proposed that paternal smoking lowers the success rates of in vitro fertilization. The findings of the current investigation were consistent with those of Mohamed A. H. A. et al. (2017), who found that seminiferous tubules had shrunk and that there were large interstitial gaps between them. Some seminiferous tubules had thicker walls, were deformed, had small diameters, and showed signs of spermatogenic cell collapse or degeneration, which resulted in the stoppage of the spermatogenic process. According to Oyeyemi, W.A., et al. (2015), smoking causes a noticeable decrease in sperm count, sperm motility, sperm viability, and normal sperm cells. Additionally, Nelson, W.O. and Patanelli, D.J. (1998) found similar findings and attributed these modifications to an increase in aberrant and degenerated cells in the testes of humans and rats as a result of the medication's systemic toxicity. In the current study, electronic cigarettes resulted in vacuole formation in seminiferous tubules but there were significant signs in this group of rats exposed to an e-cigarette, where the results show that the epididymis was more affected compared to the group exposed to conventional cigarette, which had more impact on the seminiferous tubules. We found that the group of e-cigarettes had hyperplasia in the tail of the epididymis. According to Wawryk-Gawda et al. (2019), exposure to e-vapour as well as smoking caused morphological and functional alterations in the seminiferous epithelium, including vacuolization, a decrease in spermatogenesis, and an increase in spermatogonia and spermatocyte death. Additionally, minor alterations in sperm morphology were noted; these alterations were more evident in rats exposed to cigarette smoke, while the male reproductive systems were marginally less impacted by vapour. According to Kamila Szumilas et al(2020) .'s research, even nicotine-free e-cigarettes include a number of dangerous chemicals, including endocrine disruptors that interfere with hormonal balance, morphology, and reproductive organ function.

Vaping as a cessation method for quitting smoking

E-cigarettes are advertised as a replacement for conventional cigarettes which promise to be less harmful compared to traditional smoking. This suggestion was due to the nature vape in e-cigarettes which is noted to depend on burning tobacco and the control of the amount of nicotine in an e-cigarette. However, much research was revealed harm effects of e-cigarettes on vital organs albeit not reach the hazardous effect of a conventional cigarette.

This part of the study focused on the prevalence of e-cigarettes among people, why people use them and if it is a cessation method or not. Smoking conventional cigarettes delivers more smoking pleasure than using e-cigarettes, according to dual users who were actively using both types of cigarettes (traditional and e-cigarette). Additionally, compared to the sentiments related to the use of an e-cigarette in the same circumstances, smoking a cigarette in a group of friends, along with a cup of coffee, after a meal, or after sex was linked with a stronger subjective experience of fulfillment. Dual users said that the key benefits of e-cigarettes over conventional cigarettes were their flavor, fragrance, and the subjective sensation brought on by inhaling and exhaling the vapour they produce.

According to the present study, some reasons may contribute to increase the in e-cigarette usage (Table 1):

- First, regarding the cost and spending money in our study we found that nearly 45% of our samples think that Tabaco smoking is more expensive than e-cigarettes and this may enhance using of e-cigarettes.
- Second, the appearance of the e-cigarette is more acceptable than the tobacco cigarette (75% suggest that).

Third, the e-cigarette can be used in places where tobacco cigarette is not allowed (nearly 51% suggest that).

Table 1: Some reasons may contribute to increase the in-e-cigarette usage

Items	Gender	Yes		Probably		No		I don't know		Fisher's Exact test	P value
		n	%	N	%	n	%	n	%		
Moving from tobacco cigarettes to E-cigarettes reduces the citizen's spending of his money	Male	55	27.9	59	29.9	79	40.1	4	2	20.518	<0.001
	Female	6	24	3	12	9	36	7	28		
E-cigarettes have a better and more acceptable appearance when smoking than tobacco cigarettes	Male	147	74.6	26	13.2	17	8.6	7	3.6	8.921	0.019
	Female	13	52	4	16	4	16	4	16		
E-cigarettes can be used in places where tobacco cigarettes are not allowed?	Male	76	38.6	46	23.8	66	33.5	9	4.6	17.919	<0.001
	Female	9	36	5	20	3	12	8	32		
E-cigarettes are less dangerous than tobacco cigarettes.	Male	91	46.2	62	31.5	28	14.2	16	8.1	7.387	0.048
	Female	5	20	11	44	5	20	4	16		
E-cigarettes are a healthy alternative to tobacco cigarettes	Male	84	42.6	49	24.9	51	25.9	13	6.6	12.516	0.004
	Female	6	24	2	8	12	48	5	20		
E-cigarettes can cause addiction to smoking tobacco cigarettes for nonsmokers	Male	33	16.8	53	26.9	93	47.2	18	9.1	10.543	0.01
	Female	7	28	12	48	4	16	2	8		

While quitting smoking is still a prominent reason given for using e-cigarettes, young individuals report using them for a variety of other reasons. In one research, 41.8% of the sample of teenagers and young adults said they had used an e-cigarette to stop smoking (Camenga DR, et al., 2016). Other incentives, such as performing "smoke" stunts, playing with cutting-edge technology, or testing flavors like cherry and bubble gum, are, nevertheless, highlighted by certain qualitative studies of young adults (McDonald EA. et al., 2015, Wagoner KG et al., 2016). In current study, we found that 62.2% is current and former tobacco smokers and 37.8% are a non-smoker. This result illustrates that there is evidence that most people use it to quit smoking (Table 2). After asking E-cigarette users about this, the answers were going toward this reason. but another group of people use it for other motivations such as doing "smoke" tricks or experimenting with new technology, and some groups of people use it because they think that e-cigarettes have significantly fewer side effects than tobacco smoking. And are healthy alternative devices to tobacco smoking? This was the opinion of up to 75% of our samples (Table 1). Some samples in our study suggest that the e-cigarette can cause addiction to tobacco smoking (nearly 30% of our sample) (Table 1). This may be due that some juice having some level of nicotine concentration and the person is addicted to this level and try to get more to reach the feeling of satisfaction.

Table 2: the opinion of participants (tobacco smoker and non-smoker) if the E-cigarette help tobacco users to quit smoking.

E-cigarettes help you quit smoking	Previous tobacco smoker?	yes		probably		no		I don't know		total
		n	%	n	%	n	%	n	%	
	Yes	59	42.70%	44	31.90%	31	22.40%	4	2.90%	138
	No	33	39.20%	27	32.10%	14	16.60%	10	12%	84
Total		92	41.40%	71	32%	45	20.20%	14	6.30%	222

While our results indicate that e-cigarettes may contribute to a rise in young adult cessation, it is important to understand them in the context of broader e-cigarette studies. E-cigarette usage was linked to higher probabilities of quitting smoking cigarettes, but only among "long-term" e-cigarette users, according to a longitudinal examination of cigarette smokers. Furthermore, among non-smokers, baseline e-cigarette usage was linked to higher risks of becoming a cigarette smoker

at follow-up, according to a longitudinal study of e-cigarette use among young adults in Switzerland (Gmel G. et al.,2016). Despite the limitations of both of these longitudinal studies, the results point to the need to prevent never smokers from using e-cigarettes and only recommend them as a potential assistance in quitting for former and current smokers. Additionally, results point to the necessity of more study on e-cigarettes as an addition to evidence-based cessation tools (such quitlines and NRTs) that are linked to increases in young adult quitting (Diemert LM. et al., 2013).

Conclusion

Both traditional and e-cigarettes have harmful to vital organs investigated in the present study, however, the conventional one had more effects. The lesser effect of e-cigarettes on the body suggests it as a replacement for conventional cigarettes or as a cessation method. The present study reveals that there are many factors, including the satisfaction with the use of e-cigarettes and the economic status of the smoker or their family may affect the replacement of cigarette types.

References

1. Adedayo AD, Tejani AA, Musa AA, Adeniyi TD. Histological study of smoke extracts of Tobacco nicotiana on the heart, liver, lungs, kidney and testes of male Sprague – Dawley rats. *Nigerian Medical Journal* 2011; 52(4): 217-22.
2. Adekomi Damilare Adedayo, A. A. Tijani1, A. A. Musa, T. D. Adeniyi. Histological study of smoke extract of Tobacco nicotian on the heart, liver, lungs, kidney, and testes of male Sprague-Dawley rats. *Nigerian Medical Journal* | Vol. 52 | Issue 4 | October-December | 2011
3. Al- Awaida W, Akash M, Aburubaiha Z, Talib WH, Shehadeh H. Chinese green tea consumption reduces oxidative stress, inflammation and tissue damage in smoke exposed rats. *Iranian Journal of Basic Medical Sciences* 2014; 17: 740-46.
4. Arany *et al.* Chronic nicotine exposure exacerbates acute renal ischemic injury *Am. J. Physiol. Ren. Physiol.* (2011).
5. Berkowitz L, Schultz BM, Salazar GA, Pardo-Roa C, Sebastián VP, Álvarez-Lobos MM, Bueno SM. Impact of Cigarette Smoking on the Gastrointestinal Tract Inflammation: Opposing Effects in Crohn's Disease and Ulcerative Colitis. *Front Immunol.* 2018 Jan 30;9:74. doi: 10.3389/fimmu.2018.00074. PMID: 29441064; PMCID: PMC5797634.
6. Camenga DR, Kong G, Cavallo DA, Krishnan-Sarin S. Current and former smokers' use of electronic cigarettes for quitting smoking: an exploratory study of adolescents and young adults. *Nicotine Tob Res* 2016;ntw248.
7. Canistro D, Vivarelli F, Cirillo S, Babot Marquillas CB, Buschini A, Lazzaretti M, Marchi L, Cardenia V, Rodriguez-Estrada MT, Lodovici M, et al: E-cigarettes induce toxicological effects that can raise the cancer risk. *Sci Rep.* 7(2028)2017.PubMed/NCBI View Article : Google Scholar.
8. Choi, Sangdun, Jayalakshmi Krishnan, and K. Ruckmani. "Cigarette smoke and related risk factors in neurological disorders: An update." *Biomedicine & Pharmacotherapy* 85 (2017): 79-86.

9. Chow JY, Ma L & Cho CH (1998). Involvement of free radicals and histamine in the potentiating action of cigarette smoke exposure on ethanol-induced gastric mucosal damage in rats. *Free Radic Biol Med* 24, 1285–1293.
10. Conklin, Daniel J., et al. "Cardiovascular injury induced by tobacco products: assessment of risk factors and biomarkers of harm. A Tobacco Centers of Regulatory Science compilation." *American Journal of Physiology-Heart and Circulatory Physiology* (2019).
11. Cooper RG. Effect of tobacco smoking on renal function. *Indian J Med Res.* 2006 Sep;124(3):261-8. PMID: 17085829.
12. Diemert LM, Bondy SJ, Brown KS, Manske S. Young adult smoking cessation: predictors of quit attempts and abstinence. *Am J Public Health* 2013;103:449–453.
13. Gmel G, Baggio S, Mohler-Kuo M, et al. E-cigarette use in young Swiss men: is vaping an effective way of reducing or quitting smoking? *Swiss Med Wkly* 2016;146:w14271.
14. Golli NE, Jrad-Lamine A, Neffati H, Dkhili H, Rahali D, Dallagi Y, El May MV, El Fazaa S. Impact of e-cigarette refill liquid exposure on rat kidney. *Regul Toxicol Pharmacol.* 2016 Jun;77:109-16. doi: 10.1016/j.yrtph.2016.02.012. Epub 2016 Feb 27. PMID: 26925498.
15. Gomez G, Lambertz I, Udupi V, Qi X, Thompson JC & Greeley GH Jr (1996). Influence of nicotine on gastrin and peptide YY in the rat. *Regul Pept* 67, 55–61.
16. Grana R, Benowitz N, Glantz SA. Background paper on E-cigarettes (electronic nicotine delivery systems). Center for Tobacco Control Research and Education, University of California, San Francisco, a WHO Collaborating Center on Tobacco Control. Prepared for World Health Organization Tobacco Free Initiative. December 2013. <http://pvw.escholarship.org/uc/item/13p2b72n>. Accessed March 31, 2014.
17. Grana RA, Ling PM. Smoking revolution? A content analysis of electronic cigarette retail websites. *Am J Prev Med.* 2014;46:395–403.
18. Halimi JM, Philippon C, Mimran A. Contrasting renal effects of nicotine in smokers and non-smokers. *Nephrol Dial Transplant* 1998; 13:940–44.
19. HuiWM, Joana H, Chen BW, Cho CH, Luk CT & Lam SK (1991). Nicotine induced gastric injury. A quantitative macroscopic and microscopic analysis of the protective effects of sucralfate and feeding. *Gut* 32, 372–376.
20. Irfan, Affan B. "The effects of nicotine and cigarette smoking on cardiac electrophysiology." (2019).
21. Ismail HAA. Protective effect of resveratrol against nephrotoxicity of nicotine in male rat: Antioxidant and histopathological approaches. *Journal of Innovations in Pharmaceutical and Biological Sciences* 2016; 3(4): 125-32.
22. Kamila Szumilas , Paweł Szumilas, Anna Grzywacz and Aleksandra Wilk. 2020. The Effects of E-Cigarette Vapor Components on the Morphology and Function of the Male and Female Reproductive Systems *Int. J. Environ. Res. Public Health* 2020, 17(17),6152; <https://doi.org/10.3390/ijerph1717615>.

23. Karayel H, Kaya B, Caydere M, Terzioğlu A, Aslan G. Prevention of unfavourable effects of cigarette smoke on flap viability using botulinum toxin in random pattern flaps: an experimental study. *Plast Surg (Oakv)*. 2015;23(3):177-182. doi:10.1177/229255031502300309.
24. Kosmider L, Sobczak A, Fik M, Knysak J, Zaciera M, Kurek J, et al. Carbonyl Compounds in Electronic Cigarette Vapors-Effects of Nicotine Solvent and Battery Output Voltage. *Nicotine Tob Res*. 2014;(16):1319–26.
25. Kovac, J.R.; Khanna, A.; Lipshultz, L.I. The effects of cigarette smoking on male fertility. *Postgrad. Med*. 2015, 127, 338–341.
26. Ma L, Wang WP, Chow JY, Yuen ST & Cho CH (2000). Reduction of EGF is associated with the delay of acetic acid-induced gastric ulcer healing by cigarette smoking. *Am J Physiol Gastrointest Liver Physiol* 278, G10–G17.
27. Maity P, Biswas K, Roy S, Banerjee RK & Bandyopadhyay U (2003). Smoking and the pathogenesis of gastroduodenal ulcer—recent mechanistic update. *Mol Cell Biochem* 253, 329–338.
28. Manchio JV, Litchfield CR, Sati S, Bryan DJ, Weinzweig J, Vernadakis AJ. Duration of smoking cessation and its impact on skin flap survival. *Plast Reconstr Surg*. 2009;124(4):1105-1117. doi:10.1097/PRS.0b013e3181b5a360.
29. McDonald EA, Ling PM. One of several ‘toys’ for smoking: young adult experiences with electronic cigarettes in New York City. *Tob Control* 2015;24:588–593.
30. Metwally FG, Karam SH, Elshazli EM, Ghaffar AA, Mahmoud AM, Aziz MA. Protective effect of curcumin on nicotine induced toxicity of liver and kidney in rats. *Review of Research* 2015; 4(5). Available at: www.ror.isrj.org. cited on sep; 2020.
31. Midhat Syed, Prenika Shangloo. 2020 Effect of nicotine smoke on liver and kidneys of adult male albino rats. Volume 4, Issue 9; September: 2020; Page No. 15-21
32. Mohamed Abdel Haye Autifi M.D, Alaa Sayed Elsaygher M.D and Mohammed AbdeLataif Almandouh. (2017) Effect of Nicotine on the Testis of Adult Albino Rat and the Possible Protective Effect of Vitamin E. *Medicine, AL-Azhar University, Egypt. Nature and Science* 2017;15(4) <http://www.sciencepub.net/nature>
33. Mohamed Abdel Haye Autifi, Alaa Sayed Elsaygher and Mohammed AbdeLataif Almandouh. Effect of Nicotine on the Testis of Adult Albino Rat and the Possible Protective Effect of Vitamin E.. *Nature and Science* 2017;15(4) <http://www.sciencepub.net/nature>.
34. Montanari, Christian, et al. "Nicotine e-cigarette vapor inhalation effects on nicotine & cotinine plasma levels and somatic withdrawal signs in adult male Wistar rats." *Psychopharmacology* 237.3 (2020): 613-625.
35. Narges El.Golli AichaJrad-Lamine^a Hajira Neffati ^aHousseem Dkhili^a Dalila Rahali ^aYosra Dallagi ^aMichele V.El May^bSalouaEl Fazaa^a. Impact of e-cigarette refill liquid exposure on rat kidney. *Regulatory Toxicology and Pharmacology* Volume 77, June 2016, Pages 109-116.
36. Nelson, W.O. and Patanelli, D.J., (1998): Normal and abnormal germinal cells of rats following administration of nicotine. *Fed. Proc.* 21; pp.437.

37. Office of the Surgeon General. E-cigarette Use among Youth and Young Adults: A Report of the Surgeon General Cdc-pdf[PDF–8.47 MB]. Washington, DC: U.S. Department of Health and Human Services, Centers for Disease Control and Prevention; 2016.
38. Oyeyemi, W.A., Shittu, S.T., Kolawole, T.A. and Akinola, A.O., (2015): Protective Effect of Vitamin E on Nicotine Induced Reproductive Toxicity in Male Rats. Igbinedion University.
39. Sabashvili, Maka, et al. "Role of Tobacco in the Development of Oral Leukoplakia and Oral Cancer." *Dentistry* 8.6 (2018): 1000495.
40. Sharma A, Lee J, Fonseca AG, Moshensky A, Kothari T, Sayed IM, Ibeawuchi SR, Pranadinata RF, Ear J, Sahoo D, Crotty-Alexander LE, Ghosh P, Das S. E-cigarettes compromise the gut barrier and trigger inflammation. *iScience*. 2021 Jan 6;24(2):102035. doi: 10.1016/j.isci.2021.102035. PMID: 33537654; PMCID: PMC7841355.
41. Soad Shaker Ali¹, Enas Ahmed Hamed², Nasra Naeim Ayuob^{1,3}, Ahmed Shaker Ali⁴ and Mansour Ibrahim Suliman⁴. Effects of different routes of nicotine administration on gastric morphology and hormonal secretion in rat. *Exp Physiol* 100.8 (2015) pp 881–895.
42. SR Orth, E Ritz, RW Schrier . The renal risks of smoking *Kidney international*, 1997-ElsevierI.
43. Toklu H, Sehrili O, Sahin H, Cetinel S, Yegen BC, Sener G. Resveratrol supplementation protects against chronic nicotine- induced oxidative damage and organ dysfunction in the rat urogenital system. *Marmara Pharmaceutical Journal* 2010; 14: 29-40.
44. Troiano, Chelsea, Zaroug Jaleel, and Jeffrey H. Spiegel. "Association of electronic cigarette vaping and cigarette smoking with decreased random flap viability in rats." *JAMA facial plastic surgery* 21.1 (2019): 5-10)
45. Trtchounian A, Williams M, Talbot P. Conventional and electronic cigarettes (e-cigarettes) have different smoking characteristics. *Nicotine Tob Res*. 2010;12:905–912.
46. Vansickel AR, Eissenberg T. Electronic cigarettes: effective nicotine delivery after acute administration. *Nicotine Tob Res*. 2013;15:267–270.
47. Vardavas CI, Anagnostopoulos N, Kougias M, Evangelopoulou V, Connolly GN, Behrakis PK. Short-term pulmonary effects of using an electronic cigarette: impact on respiratory flow resistance, impedance, and exhaled nitric oxide. *Chest*. 2012;141:1400–1406.
48. Vivarelli F, Canistro D, Cirillo S, Cardenia V, Rodriguez-Estrada MT, Paolini M. Impairment of testicular function in electronic cigarette (e-cig, e-cigs) exposed rats under low-voltage and nicotine-free conditions. *Life Sci*. 2019 Jul 1;228:53-65. doi: 10.1016/j.lfs.2019.04.059. Epub 2019 Apr 25. PMID: 31029780.
49. Wagoner KG, Cornacchione J, Wiseman KD, et al. E-cigarettes, hookah pens and vapes: adolescent and young adult perceptions of electronic nicotine delivery systems. *Nicotine Tob Res* 2016;18(10):2006–2012.
50. Wawryk-Gawda, E.; Zarobkiewicz, M.K.; Chłapek, K.; Chylińska-Wrzos, P.; Jodłowska-Jędrych, B. Histological changes in the reproductive system of male rats exposed to cigarette smoke or electronic cigarette vapor. *Toxicol. Environ. Chem*. 2019, *101*, 404–419.

51. Whittle BJR. The defensive role played by the gastric microcirculation. *Methods Find Exp Clin Pharmacol* 1989;11(Suppl1):35-43.
52. Yamamoto Y, Isoyama E, Sofikitis N, Miyagawa I. Effects of smoking on testicular function and fertilizing potential in rats. *Urol Res.* 1998;26(1):45-8. doi: 10.1007/s002400050022. PMID: 9537696.