SCHOLASTIC:
Journal of Natural and Medical Education
Volume 2 Issue 4, Year 2023 ISSN: 2835-303X
https://univerpubl.com/index.php/scholastic

Significance of Endobronchial Diagnostic Methods (Brash Biopsy and Bronchoalveolar Lavage) of Respiratory Virus Infections

Ishankulova Dilorom Kamarovna
Associate Professor, Department of Internal Medicine, Faculty of Pediatrics, Samarkand state medical university, Samarkand, Uzbekistan

Article Information

Received: February 27, 2023
Accepted: March 28, 2023
Published: April 29, 2023

Keywords: *Acute protracted bronchitis, persistent viral-bacterial infection, brush biopsy, bronchoalveolar lavage.*

ABSTRACT

The predominant role of endobronchial diagnostic methods (brash biopsy and bronchoalveolar lavage) in the detection of viral and bacterial pathogens in the formation and maintenance of chronic inflammation at the level of small bronchi in patients with acute protracted bronchitis has been confirmed.

Relevance. In connection with the introduction of new technologies into clinical practice (including high-resolution computed tomography), interest in small airway diseases has increased significantly in recent years. Most lung diseases are somehow connected with the pathology of the bronchi - an inseparable part of the respiratory system. Examination of sections of the tracheobronchial tree accessible to the bronchoscope provides important information about the presence and localization of various pathologies of the respirator. Visual diagnosis is the basis of the diagnosis, but a biopsy is needed for verification[1,2]. A biopsy in the lumen of the trachea and bronchi is performed using various types of nippers, as well as brush-scarifiers (brush biopsy). A clear advantage of brash-biopsy was revealed in comparison with the traditional methods used, which made it possible to check the process in 85% of the examined patients [3,4]. Bronchoalveolar lavage (BAL) is also used to study changes in the most distal airways and alveoli. With infections of the respiratory tract, with interstitial lung diseases that seriously affect the bronchioles, as well as with diseases of the large bronchi (bronchial asthma, bronchiectasis, chronic obstructive pulmonary disease) and other diseases of the small airways (bronchioles) are not uncommon. The main cause of acute bronchiolitis are viral infections: adenovirus, respiratory syncytial (RS), influenza type A, parainfluenza, coronavirus, mycoplasma [5,6]. However, with protracted (APB) and recurrent (RB) acute bronchitis with symptoms of bronchial hyperreactivity (BHR), whether bronchioles are affected - airways with a diameter of less than 2-3 mm that do not have a cartilaginous base and mucous glands. (7,8). At the same time, a chronic process associated with the development of productive sclerotic inflammation is formed. Concentric constrictions due to partial or complete obliteration of terminal bronchioles and small bronchial passages by fibrous tissue lead to impaired pulmonary blood flow and the development of emphysema (9,10). One of the reasons for the occurrence of bronchial obstruction, manifested in the form of BHR, is the important role of the inflammatory

© 2023 by the authors; licensee MDPI, Basel, Switzerland. This article is an open access article distributed under the terms and conditions of the Creative Commons Attribution License (http://creativecommons.org/licenses/by/4.0/).

component, which provides active chemotaxis of neutrophils to the site of injury.The leading role belongs to the associated and persistent viral-bacterial nature (11,12). In the acute phase of respiratory viral infections, neutrophils enter the respiratory tract. As a result, neutrophils adhere to the epithelium with the virus. The association of microorganisms such as Str. pneumoniae, H. influenzae and Br. catarralis creates fertile ground for them as a result of damage to the bronchopulmonary epithelium.

The purpose of the study was to study some features of the viral-bacterial spectrum of pathogens in patients with acute prolonged bronchitis using endobronchial diagnostics (brush biopsy and BAL).

Materials and methods. 39 patients with obstructive diseases were examined, 23 of them were complicated by bronchial hyperreactivity (BHR). The age of patients is from 21 to 60 years, most of the patients are from 21 to 40 years (0.64); Patients over 40 years old accounted for 0.36.

All patients underwent virological, microbiological and immunological examination of bronchoalveolar lavage fluid (BALF) and blood serum.

Initial materials for virological and microbiological examination of patients: nasopharynx, bronchi, BAL, brush-biopsy of the mucous membrane, bronchial lavage. Detection of viral agents was carried out by direct and indirect immunofluorescence or enzyme immunoassay methods. In this category of patients, the diagnosis of APB was made by us and was based on a combination of anamnestic data and previously identified characteristic symptoms of the disease, additional examination methods. Patients were observed for 3 years or more with a long course and complete recovery. Dynamic examination of patients was carried out for the main viral and microbial pathogens at different stages of the disease: a protracted course and after 7-14 days.

Brush biopsies were taken with sterile bronchoscope brushes into centrifuge tubes containing sterile medium (medium 199 or sterile medium supplemented with 300 units of penicillin and 300 units of streptomycin per 1 ml of medium to prevent bacterial contamination). BAL was collected in sterile tubes during therapeutic or diagnostic fiberoptic bronchoscopy. In the period of exacerbation of the disease, all of the listed materials are very promising (brush biopsy of the mucous membrane of the nasopharynx, bronchi and BAL). The most informative study of biomaterials from the deep parts of the respiratory tract during remission (bronchial brush biopsy, BAL). Bronchial washings and ALS are the main material for the identification of bacterial agents. Quantitative and cultural studies of bronchial contents were carried out. Diagnostic criteria are the concentration of respiratory pathogens ≥10 3-4 CFU/ml for invasive material and ≥10 6 CFU/ml for sputum.

Results. In the APB subgroup without BHR, the duration of the disease was mainly 8 weeks or more - (f=0.71), from 3 to 5 weeks - f=0.21 and from 5 to 8 weeks - f=0.07. Significant differences with the previous subgroup were obtained by analyzing the duration of the disease in patients with obstructive diseases with GR. Thus, in all patients of this subgroup, the duration of the disease is more than 8 weeks (f=1.0); $p > 0.01$. Almost half of the patients (48.3%) had viral antigens, and PS- and adenoviruses were recorded in equal proportions (Fig 1). Only a few people registered parainfluenza (1.9%), type 1 herpes. RS- and adenoviruses were the most common viral agents in patients with post-infectious disease associated with AB. Presence of other pathogens: influenza A viruses (f=0.36), parainfluenza (f=0.09), Mycoplasma pneumoniae (f=0.09) (Fig 2). There were also active f=0.93 and associated infection variants (f=0.79). The diagnostic criterion was repeated detection of an identical infectious agent in combination with an elevated level of antibodies (>1:160), which can fluctuate over long periods of observation from 1:80 to 1:640 depending on the timing of the onset of a chronic infectious process, the presence of an additional acute infections, etc. It was found that the frequency of detection of an infectious process in the deep sections of the bronchial tree was 66–74%. In the remission phase,

© 2023 by the authors; licensee MDPI, Basel, Switzerland. This article is an open access article distributed under the terms and conditions of the Creative Commons Attribution License (http://creativecommons.org/licenses/by/4.0/).

this indicator was significantly lower. In the stable period, the main respiratory pathogens S. pneumoniae (53.6%) and H. influenzae (21.4%) and their association (9.5%) represented the basis of the bacterial spectrum. Pneumococcal infectious process was detected in 64-84% of patients during the period of exacerbation. H. Influenzae was detected most often in the group of patients with severe obstructive disorders. The infectious process, caused simultaneously by the association of S. Pneumoniae and H. influenzae, was significantly significant only in the period of exacerbation of the disease. Antibody titer ≥1:640 or 4-fold seroconversion during the study period served as a diagnostic sign for the assessment of specific humoral immunity.

During follow-up, high levels of antibodies to S. pneumoniae and H. influenzae remained in remission with a geometric mean titer of 1:658. The indicators of the serological study and their dynamics corresponded to the results of the microbiological study. Antibodies to pneumococci were detected in 4/5 patients at both stages of the disease. With an active inflammatory process, antibodies to H.influenzae were detected somewhat less frequently (49.1%) than to pneumococci (77.8%), and the lowest level of antihemophilic antibodies was in the stable period of the disease (28%). In the stage of clinical remission, elimination of the pathogen in some patients did not affect the average contamination of the pathological material with pneumococci and Haemophilus influenzae. In a number of cases, species similar to fungi Staphylococcus aureus and Candida were found. The concentration of all pathogens presented in the studied bronchial contents significantly exceeded the established diagnostic titer (103-104 CFU/ml), and the geometric mean concentration was 5.3 lg/ml.

Fibrobronchoscopy was performed in 17 patients, of which almost 2/3 (f-0.71) had diffuse catarrhal endobronchitis, 2 (f-0.12) patients had atrophic changes in the bronchial mucosa and 3 (f-0,18) the picture in FBS was normal. During FBS, carried out in 7 patients with APB with BHR, diffuse moderately pronounced catarrhal endobronchitis was detected in 5 (f-0.7), in one case (f-0.14) bilateral significantly pronounced endobronchitis was noted, and in the other (f-0.0 ,14) – the endoscopic picture was without inflammatory changes. In three cases with APB (f-0.18) and in one case with APB with BHR (f-0.14) there was a tendency to subatrophy of the mucosa.

Thus, the long-term inflammatory process in patients with APB is characterized by a high participation of viruses, pneumococci, and H. influenzae. At the same time, we found that even in the period of clinical remission, a high frequency of detection of viral and bacterial respiratory agents remains, along with the presence of diagnostically significant levels of antibodies to them in the blood serum. This indicates the main etiopathogenetic significance of PS- and adenoviruses, S.pneumoniae, H.influenzae.

Discussion. The results obtained indicated an active inflammatory process in the distal parts of the bronchial tree in patients with acute bronchitis, both during the period of protracted course and during remission**.** A characteristic feature was an increase in the proteolytic activity of serum levels of myeloperoxidase (MPO) and neutrophil elastase (NE) in this group of patients. Isolation of MPO and NE is associated with the presence of a persistent viral-bacterial infection of the peripheral parts of the bronchial tree, primarily caused by PS- and adenoviruses, as well as pneumotropic bacteria S. pneumoniae, H. influenzae. A direct correlation ($r=0.61$; $p\leq0.05$) was established between the content of MPO and the degree of colonization of the bronchial contents of the studied patients with pneumotrophic bacteria. This fact indicates the progression of the compensated infectious process during the period of clinical remission. Clinically, APB is characterized by an active degree of bronchial obstruction, an undulating course.

Conclusions. Thanks to the development and creation of new models of endoscopes and instruments, the diagnostic capabilities of tracheobronchoscopy increase every year. Determination of the role of viral and bacterial pathogens and immune mechanisms in the

© 2023 by the authors; licensee MDPI, Basel, Switzerland. This article is an open access article distributed under the terms and conditions of the Creative Commons Attribution License (http://creativecommons.org/licenses/by/4.0/).

formation and maintenance of chronic inflammation in OBA, in addition to anamnestic, clinical, functional and radiological diagnostic methods, brush biopsy, BAL, is of great importance and allows expanding therapeutic approaches in the treatment of patients, as well as carrying out targeted prevention. This contributes to the stabilization of the clinical picture of the disease.

Fig.1. Detection of viral antigens in epithelial cells during brush biopsy of the nasopharyngeal mucosa of patients with obstructive diseases (f)

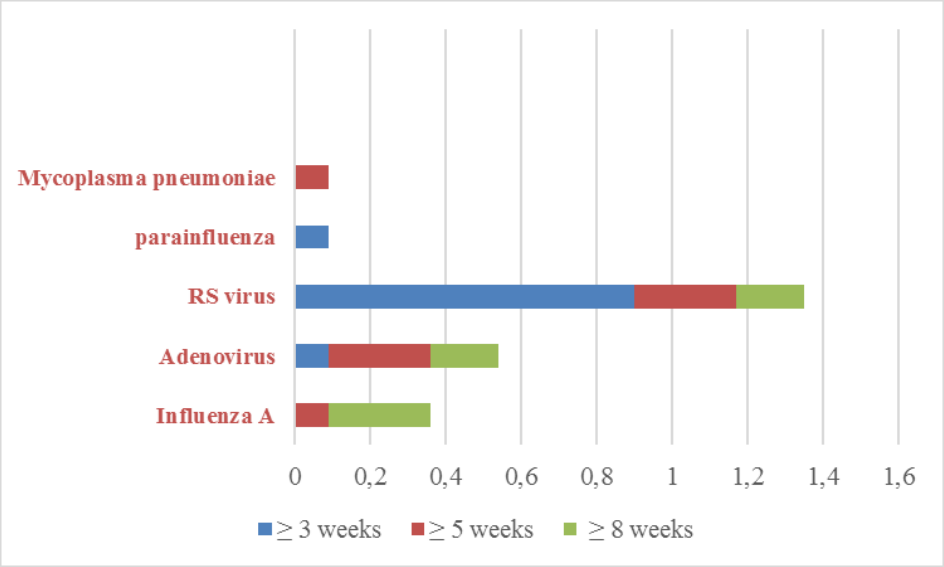

Fig.2. Detection of viral antigens in epithelial cells during brush biopsy of the nasopharyngeal mucosa of patients (f)

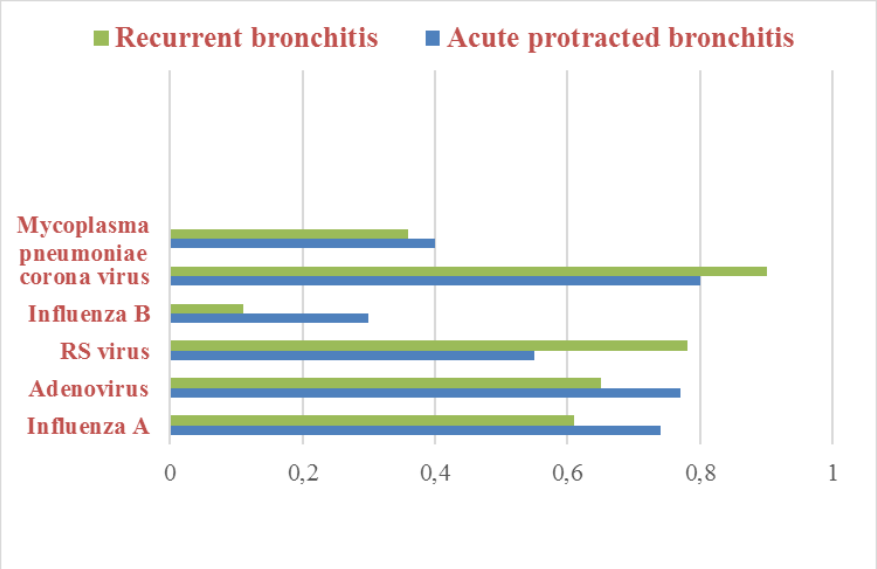

REFERENCES

1. Kamarovna I. D. SURUNKALI BRONXITNING TASNIFI, DAVOLASI VA OLDINI OLISH TAMOYILLARI BORASIDA //IQRO JURNALI. – 2023. – Т. 2. – №. 2. – С. 51-57.
2. Ишанкулова Д. К. Клиническое значение вирусной инфекции и иммунореактивности у больных хроническим бронхитом с элементами бронхоспазма //International scientific review. – 2019. – №. LXV. – С. 96-99.

© 2023 by the authors; licensee MDPI, Basel, Switzerland. This article is an open access article distributed under the terms and conditions of the Creative Commons Attribution License (http://creativecommons.org/licenses/by/4.0/).

3. Ишанкулова Д.К. Однонаправленность этио-патогенетических изменений у больных острым и хроническим бронхитом как реальность хронизации воспалительного процесса в бронхах. Journal of Cardiorespiratory research. Инновационный прогресс в исследованиях внутренней медицины. Материалы международной научно-практической конференции. Сам.2021. С 23-24.
4. Ишанкулова Д.К. Эффективность применения адаптогенов при формировании противовирусного иммунитета. XI Международные Авиценновские чтения научно-практическая конференция. Абу Али Ибн Сино (Авиценна) и Covid-2019. Бухара-2021, ноябрь. С. 22-23.
5. Ishankulova D.K. Intensiv terapiya bo'limi sharoitida gospital infeksiya bemorlar immun reaktivligining og'irlashtiruvchi omil sifatida. Журнал кардиореспираторныхисследований. Инновационные технологии в здравоохранении: новые возможности для внутренней медицины: Материалы международной научно-практической конференции. Сам., -2022 г. С 674-677.
6. Ishankulova , D. (2022). O'TKIR CHO'ZILGAN BRONXITNING SURUNKALI BRONXIT SHAKLLANISH BOSHQICHI SIFATIDAGI KLINIK XUSUSIYATLARI. Eurasian Journal of Medical and Natural Sciences, 2(6), 493– 497. извлечено от https://www.inacademy.uz/index.php/EJMNS/article/view/2655
7. Ishankulova, D. K. (2022). The Formation of Mucociliary Insufficiency in the Bronches on the Role of Respiratory Viral Infection. Journal of Pharmaceutical Research International, 1. https://doi.org/10.9734/jpri/2022/v34i34a36139
8. Ishankulova, D. K. (2022). The formation of mucociliary insufficiency in the bronches in respiratory viral infection. International Journal of Health Sciences, 6(S3), 4846–4851. https://doi.org/10.53730/ijhs.v6nS3.6968
9. Дилором, К. И. (2022). Эффективность противовирусного лечения больных острым затяжным и рецидивирующим бронхитом. Eurasian Journal of Medical and NaturalSciences, 2(5), 253–258. извлечено от https://www.inacademy.uz/index.php/EJMNS/article/view/1650
10. Nasirova A. A. et al. Features Of Immunological Indicators In Patients With Chronic Obstructive Lung Disease And Bronchial Asthma //Solid State Technology. – 2020. – Т. 63. – №. 6. – С. 6873-6880.
11. Ishankulova D.K.The effects of respiratory viral infection in combating Avicenna's legacy. American Journal of Social and Humanitarian Research. Volume: 3 ISSN: 2690-9626. Publication Year: 2022. P. 378-383.
12. Кокосов А. Н., Александрова Н. И., Ишанкулова Д. К. Классификация, принципы лечения и профилактика хронического бронхита. – 1991.
13. Ruziyeva A.A, Ishankulova D.K.,Nizomov B.U. Verification of dyspnea according to external respiratory function in patients with bronchial asthma. International journal on oranje technologies Volume:03 (30 -33) Issue: 02/ February 2021.

© 2023 by the authors; licensee MDPI, Basel, Switzerland. This article is an open access article distributed under the terms and conditions of the Creative Commons Attribution License (http://creativecommons.org/licenses/by/4.0/).